

Choroidal Neovascularisation In A Case Of Central Serous Retinopathy

Dr. Kshama Dwivedi¹, Dr. Ravindra Kumar², Dr. Vibha Singh³, Dr. Harsh Mathur⁴

¹(M.B.B.S., M.S)Assistant Professor

²(M.B.B.S., M.S)Senior resident

³(M.B.B.S., M.S.)Senior resident

⁴(M.B.B.S)Junior resident

Abstract: Central serous retinopathy is commonly acquired macular disorder, seen more frequently in males of young males who have type A personality. But this is the case of sixteen year old female who experienced recurrence after 1.25 years of initial episode. The recurrence was associated with choroidal neovascularization, though there were no predisposing factors. High degree of suspicion led to early detection and prompt treatment of choroidal neovascularization, which restored the vision. So regular follow up of these patients and high index of suspicion in atypical cases is very important.

I. Case Report

A sixteen year old female patient developed central serous chorioretinopathy(CSR) in her right eye in December 2013. Optical Coherence Tomogram (OCT)revealed a localized neurosensory detachment. She was kept on observation and advised Nepafenac eye drops three times a day. It resolved spontaneously as evident on OCT at two months. Patient gained vision 6/6 with correction. There was no complaint regarding quality of vision.

Patient presented again in March 2015 with history of positive scotoma in right eye with mild diminution and distortion of vision. On examination vision with pin hole and with glass was 6/6P. Fundus examination revealed slight elevation at macula. We diagnosed it as a case of recurrent CSR, and advised Nepafenac eye drop and observation.

Patient presented two days later with increase in size of scotoma and sudden gross diminution of vision. Vision with glass and with pin hole was finger counting(FC). Anterior segment was normal. Fundus examination revealed mild elevation at macula along with few hypopigmented patches surrounding fovea. Fundus fluorescein angiography(FFA) was planned. Itrevealedhyperfluorescence seen in areas inferior to and nasal to fovea. The hyperfluorescent spot present nasal to fovea was seen leaking in early phase and was diagnosed as site of recurrent CSR. The hyperfluorescent spot located inferotemporal to fovea appeared in late phase, has fuzzy margins and gradually increased in size. Choroidalneovascular membrane (CNVM) was suspected at this foci. OCT was done, which revealed small amount of subfovealf fluid(SRF).

Diagnosis of CNVM was made. Although no clear membrane was seen on OCT, yet a provisional diagnosis of occult CNVM was based on- sudden gross diminution of vision with a central scotoma, late leakage seen on fundus fluorescence and presence of subretinal fluid. Many times occult CNV cannot be localized on OCT¹. Three intravitrealinjectionsofLucentis 0.5 mg in 0.05 ml(i.e.10 mg /ml) were givenat one monthly interval. Vision improved to 6/6 with correction finally. Left eye was unaffected in both the situations. Patient is a case of myopia of 1.5 diopters.

II. Discussion

CSR is an acquired macular disorder with unknown etiology, characterized by serous detachment of the neural retina in macular region. Commonly seen in males of 20 to 50 years, although age and sex is no bar. Presenting features are usually metamorphopsia, blurred vision and micropsia. It was first described in literature by Von Graefe who considered it to be retinitis. Other names which were suggested were retinopathiacentralis serosa or central serous retinopathy. The most commonly used term "Central Serous Chorioretinopathy", was coined by Donald Gass (1960)².

Pathogenesis is still not very clear. The subneural fluid is believed to originate from choroid. There is also an abnormal focal defect at the level of retinal pigment epithelium (RPE). Prunte and Flammer³ proposed that localized capillary and venous congestion in choroid impairs the circulation, produces ischemia which allows increased choroidal exudation and a focally hyperpermeable choroid. This produces RPE detachment.

Growth of RPE detachment ruptures the tight junctions of RPE. This defect of outer blood retinal barrier (RPE) allows the fluid which has leaked from choroid to pass above and cause a neurosensory detachment.

CSR tends to resolve spontaneously and completely in 90% cases in few months⁴. Poor visual acuity at presentation and prolonged detachment are associated with poor visual outcomes. Upto 50% patients might develop recurrence. Half of the patients who develop recurrence develop it within a year. Some patients develop permanent visual loss due to complications like- retinal pigment epitheliopathy, cystoid macular degeneration and choroidal neovascularization (CNV in about 6% of cases). Even the patients who gain 6/6 vision; sometimes complain of metamorphopsia, scotoma and reduced contrast sensitivity. Hence, every patient of CSR must be followed carefully.

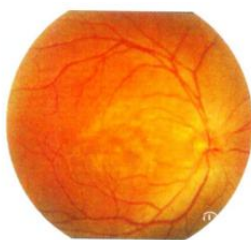CNV cases in CSR have been reported by multiple authors. Flynn et al (Retina 2002)⁵ reported 8% incidence of CNV in CSR patients but they had a poorer visual acuity. Chan et al⁶ (AJO 2007) treated two cases of CNV due to CSR with three injections of Bevacizumab at monthly interval and all of them gained good vision. Lip et al⁷ (BJO 1999) mentions a case of CSR which developed CNV seven months after CSR. S.Mandale et al⁸(IJO 2011) reported a case of subfoveal CNV complicating an active CSR.

CNV in CSR is well known. But the case reports which have been mentioned in literature are either associated with multiple recurrences or have received laser – both of which are known predisposing factors for CNV. But in this case neither of these predisposing factors are present. The patient had single episode of CSR in the same eye almost a year back. Then she developed CNV. CNV associated with CSR is usually of occult type. Treatment with Lucentis injections restored her visual acuity to 6/6.

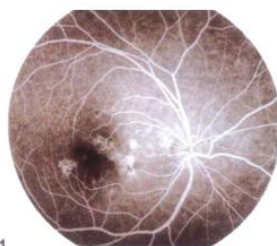
References

- [1]. Liakopoulos S, Ongchin S, Bansal A, Msutta S, Walsh AC, Updike PG et al. Quantitative optical coherence tomography findings in various subtypes of neovascular age related macular degeneration. Invest Ophthalmol Vis Sci 2008;49(11):5048-5054.
- [2]. Liegl R, Ulbig MG. Central serous chorioretinopathy. Ophthalmologica 2014;232:65-76.
- [3]. Prunte C., Flammer J.: Choroidal capillary and venous congestion in central serous choroidopathy. AJO1996;121:26-34.
- [4]. Aggio FB, Roisman L, Melo GB et al. Clinical factors related to visual outcome in central serous chorioretinopathy. Retina 2010;30(11): 28-34.
- [5]. Loo HR, Scott IU, Gass JDM, Flynn HW, Murray T, Smiddy WE et al. Factors associated with reduced visual acuity during long term follow up of patients with idiopathic central serous retinopathy. Retina 2002Feb ;22(1):19-24.
- [6]. Chan WM, Lai TY, Liu DTL et al. Intravitreal Bevacizumab (Avastin) for choroidal neovascularization secondary to punctate inner choroidopathy of idiopathic origin. AJO 2007, 143(6):977-983.
- [7]. Lip P, Dixon L, Ross M et al. Central serous retinopathy complicated by massive bilateral subretinal haemorrhage. BJO 1999;83(8):987.
- [8]. Mandal S, Sinha S, Abbas Z et al. Intravitreal Bevacizumab for subfoveal choroidal neovascularization complicating active central serous chorioretinopathy. IJO 2011;59(4):338-339.

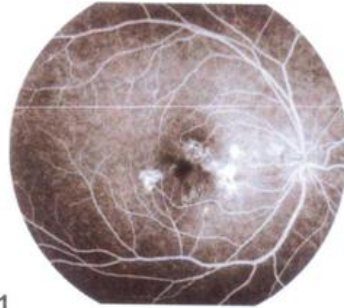
FFA in the recurrent episode



Fundus showing oedema at macula with few hypopigmented patches

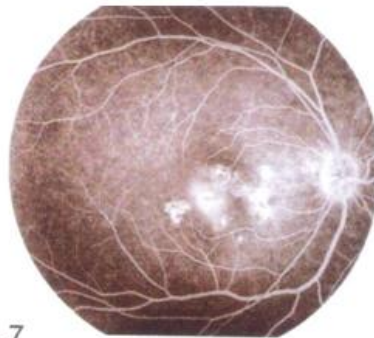


FFA showing hyperfluorescent spot nasal to fovea in early phase –recurrent CSR



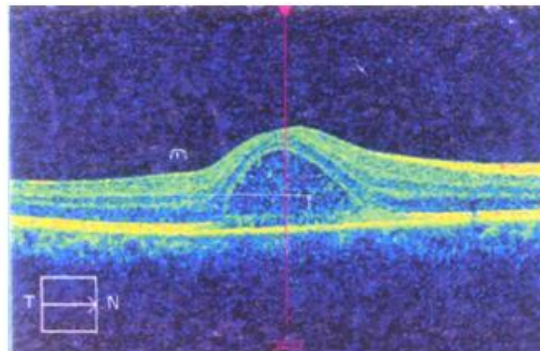
2:00.1

Hyperfluorescent spot inferotemporal to fovea appeared in late phase with fuzzy margins-suspected CNV

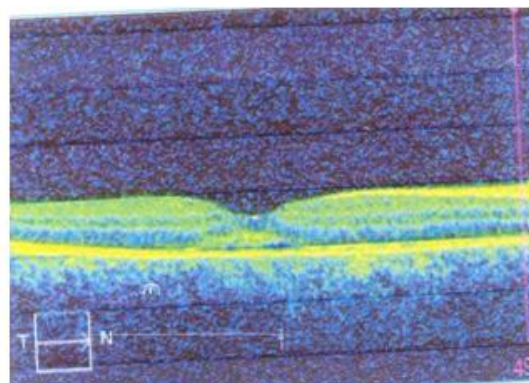


11:24.7

CNVM leak gradually increased in size in late phase



Initial presentation showing CSR



Recurrent episode showing mild subretinal fluid